



Conjoined Siamese Twins Incidence Delivered by Caesarian Section- A Case Report



Michael Osei Appiah*

College of Animal Science and Technology, China

*Corresponding author: Michael Osei Appiah, College of Animal Science and Technology, China

Submission: 📅 December 04, 2018; Published: 📅 December 11, 2018

Abstract

Introduction: A very rare case of Siamese twins assembled in the abdomen was delivered through Caesarean section.

Case presentation: We present a case of a 28-year-old, female, Ghanaian mother who had conjoined twins at the abdomen.

Conclusion: Mother of Siamese twins was however shocked that all her scans at the same hospital did not reveal the condition of her baby until they were born. The first genetic defects of interest can now be identified before delivery. Such a serious injury, as is the case with our index, which is incompatible with postpartum life, needs to be consulted. If properly reported supervision is adequately detected during postnatal care, it can mean that pregnancy is due to a close delivery

Introduction

The combined twins are identical twins whose bodies are included in the uterus [1]. This is a rare event with incidents of 1 in 50,000-100,000 births. Events in Africa and Southwest Asia are somewhat more incidental [2]. The combined survival rate for connecting twins is approximately 25% [3] and this situation occurs more frequently between women, [2] with a ratio of 3:1. It is rare to see a twin-linked reaching up to term. The present case takes attention because the twin twins are very rare, given that this incidence was the first of its kind in the facility.

Case Presentation

A 28-year-old mother at Ejura Sekyedumase District in the Ashanti region of Ghana had Siamese twins incidence conjoined in her abdomen at the Ejura government hospital. From the medical practitioners, they would need sophisticated equipment to separate the twins, adding that the conjoined twins would be referred to a tertiary health institution (Komfo Anokye Teaching Hospital) in the country as the mother's delivery was not smooth and that they were conjoined twins so Cesarean Section had to be performed after the mother had undergone a similar surgery two years ago.

The C-section started at about 6:30pm and ended at 7pm night. And according to the medical superintendent who carried out the C-section, the conjoined twins were very rare, noting that the case was the first of its kind to be recorded at the facility but that is not the first for Dr. Manye to have carried out in the country. Five years ago, he performed a more complicated case at New Edubiase hospital in the Ashanti region. In that case, the twins shared vital organs like the heart and lung which were very delicate. However, according to the medical practitioner, the children died shortly after delivery

because the scan failed to indicate they were conjoined and doctors could not have considered a C-section. The team had to perform other functions to save the life of the woman. But in this case, the mother of the Siamese twins shared her experience with the news media and that she was recovering enough to care for her children. Below is the photo image of the babies delivered by caesarian section (Figure 1 & 2).



Figure 1:

Discussion

There are different types of twins shown in the following types of combinations, out of which only 60% are born alive [4,5] (Table 1).

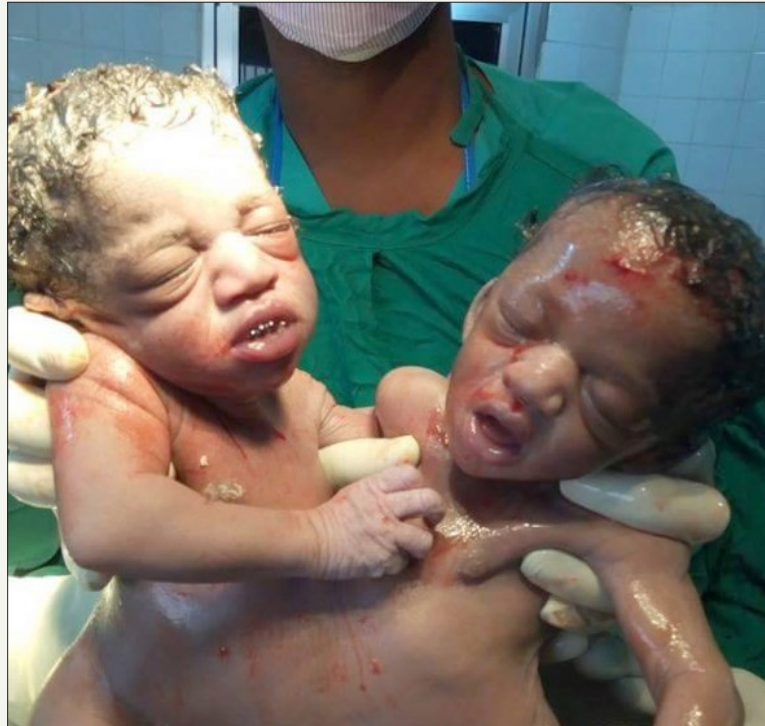

Figure 2:

Source: Ghana | myjoyonline

Table 1:

Type	%
Thoraco Omphalopagus	28.4
Thoracopagus	18.5
Omphalopagus	9.9
Parasitic Twins	9.9
Craniopagus	6.2
Others	36.1

Postpartum trips ensure that the complications of pregnancy are easily raised and rare events such as twin twins can be easily diagnosed on fetal ultrasonography. It should be suspected whenever there is a diagnosis of monochromic monoamniotic twin, fetal bodies never seen separately on regular USG, the presence of multiple vessels in umbilical cords and detection of other anomalies [6]. Once the different placentas are not seen or the intermediate film is not seen, the combined twins can be excluded. Color Doppler two-dimensional ultrasound has become an important prenatal diagnostic tool for the diagnosis of conjoined twins from 11 to 14 weeks [7,8].

The delivery of conjoined twins is the next important decision. Because obstruction is inevitable, vaginal delivery in conjoined twins is virtually impossible unless the fetus is macerated or prematurely delivered [9,10]. If the fetus is viable, they need to be delivered by caesarean section. When they are not viable, they still need caesarean section because of dystocia, unless they are very small, and then vaginal delivery may succeed [11]. The present case

stands out because the patient had the siamese twins conjoined in the abdomen and the only means was by caesarian section to deliver the babies [12-14].

Conclusion

Siamese twins are an uncommon phenomenon and their vaginal delivery is a rare event. Prenatal care and proper care will ensure that the accidents cited in this report are averted.

Acknowledgement

The author appreciates the contributions Dr. Mensah Manye (medical superintendent) who carried out the C-section and all the nursing staff of the Ejura government hospital pediatric surgery unit in the care of these twins during the Caesarian section.

Conflicts of Interest

There is no conflict of interest to declare.

References

1. <http://umm.edu/programs/conjoined-twins/facts-about-the-twins>.
2. Carnevale FC, Borges MV, Affonso BB, Pinto RA, Tannuri U (2006) Importance of angiographic study in preoperative planning of conjoined twins: case report. *Clinics (Sao Paulo)* 61 (2):167-170.
3. James LS, James TG (2006) The craniopagus malformation: classification and implications for surgical separation. *Brain* 129(5): 1084-1095.
4. Edmonds LD, Layde PM (1982) Conjoined twins in the United States, 1970- 1977. *Teratology* 25(3): 301-308.


5. Rudolph AJ, Michaels JP, Nichol BL (1967) Obstetric management of conjoined twins. *Birth Defects* 3: 1-28.
6. Koontz WL, Herbert WN, Seeds JW, Cephalo RC (1983) Ultrasonography in the antepartum diagnosis of conjoined twins: A report of two cases. *J Reprod Med* 28(9): 627-630.
7. Pajkrt E, Jauniaux E (2005) First-trimester diagnosis of conjoined twins. *Prenatal Diagn* 25(9): 820-826.
8. Vural F, Vural B (2005) First trimester diagnosis of dicephalic parapagus conjoined twins via transvaginal ultrasonography. *J Clin Ultrasound* 33(7): 364-366.
9. Osmanağaoğlu MA, Aran T, Güven S, Kart C, Özdemir Ö, et al. (2010) Thoracopagus conjoined twins: a case report. *Obstet Gynecol* 2011:238360, doi: 10.5402/2011/238360.
10. Kamalian N, Shirani S, Soleymanzadeh M (2011) Thoraco- omphalo- ischiopagus tripus conjoined twins: Report of a case. *J Forensic Res* 2: 117.
11. Van Den brand SFJJ, Nijhuis J G, Van Dongen PWJ (1994) Prenatal ultrasound diagnosis of conjoint twins. *Obstet Gynecol Survey* 49(9): 656-662.
12. <https://www.ghanaweb.com/GhanaHomePage/NewsArchive/I-was-frightened-when-I-saw-my-babies-Mother-of-Siamese-twins-659185?gallery=1>
13. <https://www.ghanagrio.com/ghana-latest-news/465129-siamese-twins-born-at-ejura.html>
14. <https://www.haotags.com/ghana-news/ejura-woman-gives-birth-to-siamese-twins/>



Creative Commons Attribution 4.0
International License

For possible submissions Click Here

[Submit Article](#)



Research in Medical & Engineering Sciences

Benefits of Publishing with us

- High-level peer review and editorial services
- Freely accessible online immediately upon publication
- Authors retain the copyright to their work
- Licensing it under a Creative Commons license
- Visibility through different online platforms